

An Integrative Guide to Sacroiliac Joint Dysfunction:

Understanding Your Low Back and Buttock Pain

By, David Mesnick, PT, OCS, cMDT

Contributions by Travis Barefoot, DPT

www.pt360atl.com

Overview

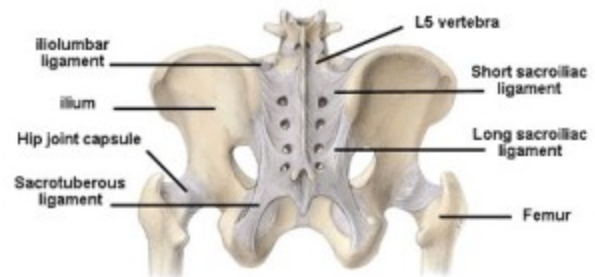


The musculoskeletal system is an intricate network of bones, muscles, and other connective tissue that serves to provide form and structure to our bodies, to produce movement, and to protect our inner organs. “(Professionals in the medical field) use manual medicine to examine this organ system in a much broader context, particularly as an integral and interrelated part of the total human organism.”⁴

“Skilled Physical Therapists are an invaluable part of a team of health professionals providing special knowledge and abilities that can enable the delivery of an effective rehabilitation process, especially for patients with musculoskeletal dysfunctions.”⁵ The information provided in this pamphlet serves to better educate you as a patient on the issues caused by the sacroiliac joint, and how Physical Therapist use certain methods to expedite the process of recovery.

Anatomy

The sacroiliac joint, abbreviated as “SI” joint, is a connection of two bones just below the lumbar vertebrae (your lower back). This joint is composed of the sacrum and ilium bones. Just as the keystone in a masonry arch serves to maintain the structural integrity of doorways and ceilings, the sacrum is a biological equivalent to the structural integrity of the pelvis.



There are 2 parts to the SI joint; on either side of the sacrum we have 2 iliums (place your hands on your ‘hips’ and you’re feeling the top of the ilium) and between the placements of your hands being on your hips lays the sacrum. This is the “SI joint”. Previous school of thought believed this joint to be relatively ‘fixed’, or extremely stable. However, more up-to-date research outlines how the mobility and synchronicity of movement at this joint plays an extremely important role in the normal motion of the human body.

Normal movement of the sacrum in relation to the ilium is described as ‘nutations’ (and conversely, ‘counter nutations’), which can be defined as oscillatory movement of the axis of a rotating body¹. Another way to think of this is to imagine the top of the sacrum moving forward and down compared to the bottom, and then the opposite would then be counter nutation. These motions occur in conjunction with other movements like walking, bending forward/backward, and even breathing!

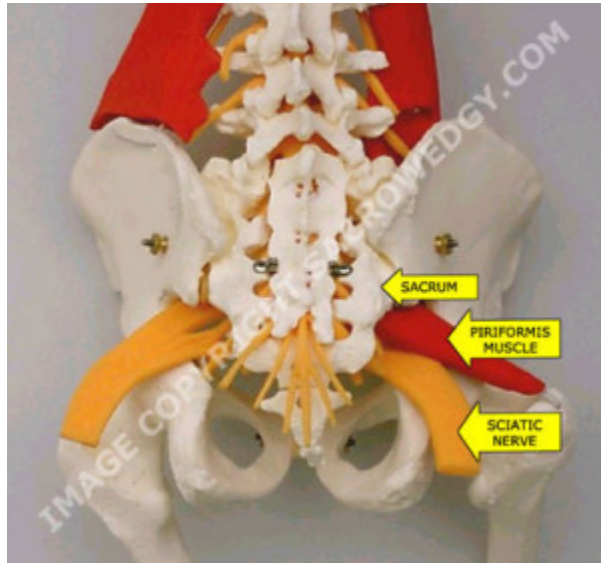


Signs and symptoms

When there is a disturbance in the normal movement of the SI joint, an array of signs and symptoms may be present. In a Physical Therapy examination, the therapist will observe the motion of the SI joint and other involved structures via special tests that are outlined in this handout. Although special tests are present to serve as a basis for examination, realize that every evaluation may vary from therapist to therapist. "People with SI joint dysfunction will have symptoms ranging from pain at the joint itself, in the lower back, or even down the thigh and groin. There may be a presence of generalized stiffness or burning sensation at the joint"². Sometimes an SI dysfunction can actually cause pain on the opposite side from where the true problem lies!³

Muscles

Piriformis



Innervated by S1 and S2

Will become overactive or facilitated with an SIJD.

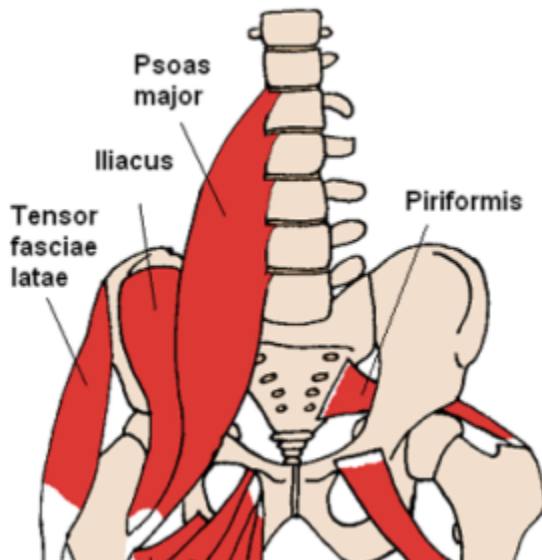
Tenderness is usually felt in the muscle belly (deep buttock pain) or at the origin (sacrum) or attachment (at the greater trochanter)

Becomes the primary stabilizer of the SIJ in the presence of SIJD which is a faulty pattern

Can compress the sciatic nerve and can cause piriformis sciatica (link) or piriformis syndrome

Over stretching often increases over activity or facilitation and leads to increased pain or sciatica.

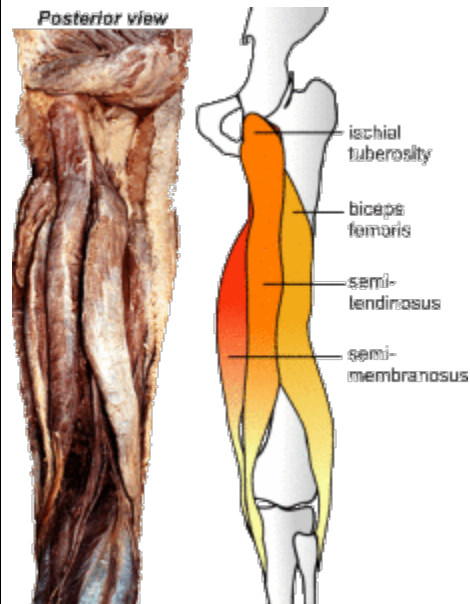
Iliopsoas (iliacus + psoas muscle)



iliacus: L2-L4 (femoral nerve) psoas: L1-L3 (anterior branches of lumbar plexus)

Dysfunction at L2-3 causes hypertonicity of the hip flexor group muscles, which can mimic a labral tear

Hamstrings

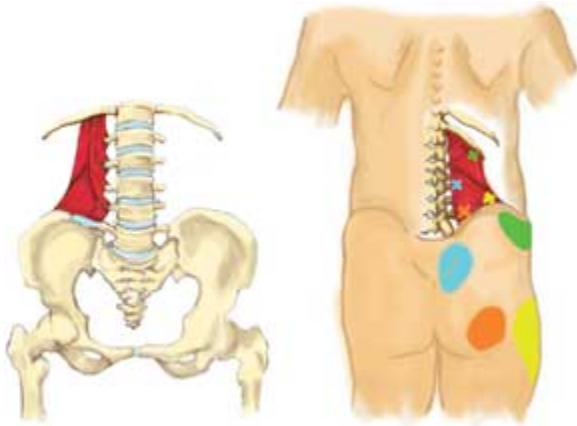


Bicep femoris: tibial nerve + common peroneal nerve, semitendinosus: tibial nerve, semimembranosus: tibial nerve

Hamstring tears are often a result of the inactivation of the gluteus maximus during athletic activity. Overactivation/facilitation of the hamstrings can be caused by sacral dysfunctions, T-L junction dysfunctions, and even ankle sprains.

Neural tension is an additional symptom of tight hamstrings. When neural tension increases, the hamstrings become shortened to protect the nerves that run down the leg (think: sciatic nerve).

Quadratus Lumborum (QL)



T11-L2 innervation

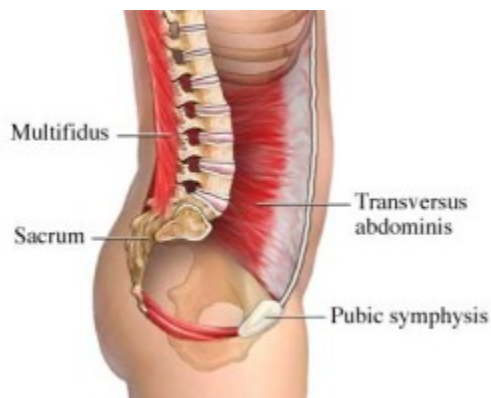
Most frequent muscular cause of back pain

Hypertonicity on one side associated with FRS dysfunction at T12-L1 to that side.

Possibly the primary stabilizer of the L-spine

Common with one sided sitters and standers in SIJD

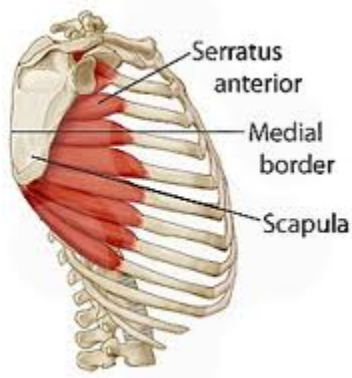
Lumbar Multifidus



Innervated by posterior branches of lumbar spinal nerves

When there is compromise to the deep layer of the spinal column (vertebrae/discs/ligaments) the multifidus, a key stabilizing muscle that normally protects the injured spinal joint, quickly shrinks by 25% and fails to activate correctly. This means the key muscles that normally keep our backs functioning properly and without pain can no longer do their job.⁸ (Jemmett)

Serratus Anterior

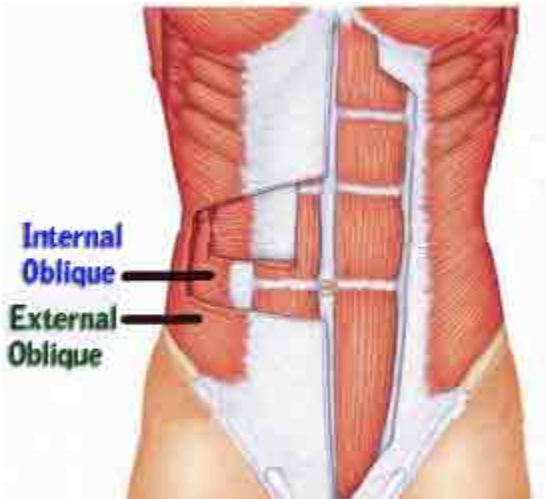


Innervation: C5-7 (long thoracic nerve)

Becomes inhibited as a result of ERS (extension) dysfunctions in the upper thoracic spine, or from a loss of inferior/posterior glide of the G-H joint

As a result of the dysfunction, scapular winging can occur. This equates to poor scapular stabilization, cervical pain, shoulder impingement, and upper trap/levator scapulae trigger points.

Internal & External Obliques



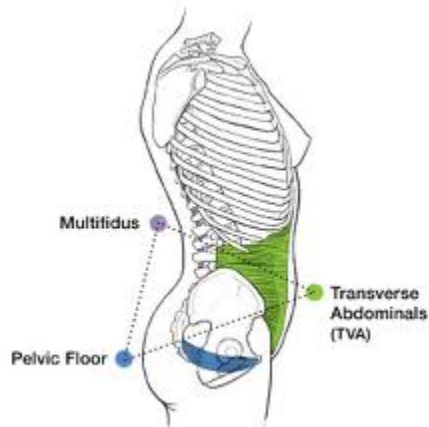
Innervation: intercostal nerves 7-12, subcostal nerve

Innervation: intercostal nerve 8-12, iliohypogastric, ilioinguinal nerves⁹

Trigger points in the external/internal obliques and transversus abdominis all have similar trigger point patterns into the abdominal cavity. Referral patterns can mimic heartburn and epigastric pain.

(www.bodyworks.com)

Transversus Abdominus



Innervation: T8-12

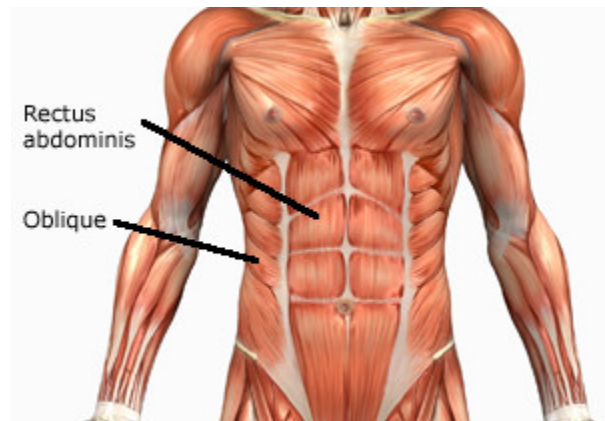
This muscle, like the multifidus, is a key player in spinal (core) stabilization in the low back. Injury to the deep layer of the spinal column results in decreased contractile ability of the “TrA”. Causes also stem from Thoraco-Lumbar junction dysfunctions and lower thoracic dysfunctions.

This leads to tight/overactive hamstrings, increased neural tension, and low back pain.

Only need 3-5% of TrA contraction for stability

Only train after mechanical dysfunction is cleared

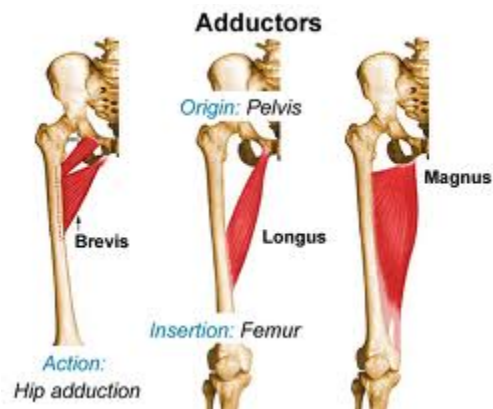Rectus Abdominus



Innervation: 7-12 intercostal nerves

A cause of dysfunction of this muscle group is an inferior pubic dysfunction on the same side as the symptoms, which are same side adductor pain and pubic pain (symphysis pubis).

Adductors



Innervation L2-L4

Are functionally connected to the abdominal oblique sling of support for the anterior pelvis

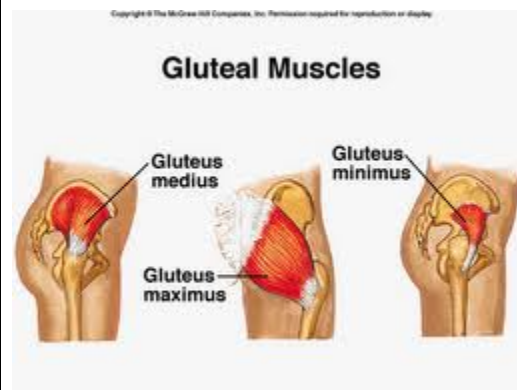When hypertonic the pull of the adductors can result in an inferior pubic shear (symphysis pubis)

Diaphragm

Innervation is the phrenic nerve C3-C5

The diaphragm functions in [breathing](#). During inhalation, the diaphragm contracts and moves in the inferior direction, thus enlarging the volume of the thoracic cavity (the [external intercostal muscles](#) also participate in this enlargement). This reduces intra-thoracic pressure: In other words, enlarging the cavity creates suction that draws air into the lungs.

Gluteus Maximus



Innervation L5, S1, S2

Primary Stabilizer of the Sacroiliac joint

Can become underactive with a Left on Right sacral torsion or Right on Left Sacral torsion, and mechanical problem at L4 or L5 on the same side

Under activity often results in chronic Hamstring tightness or injury.

Gluteus Medius and Minimus

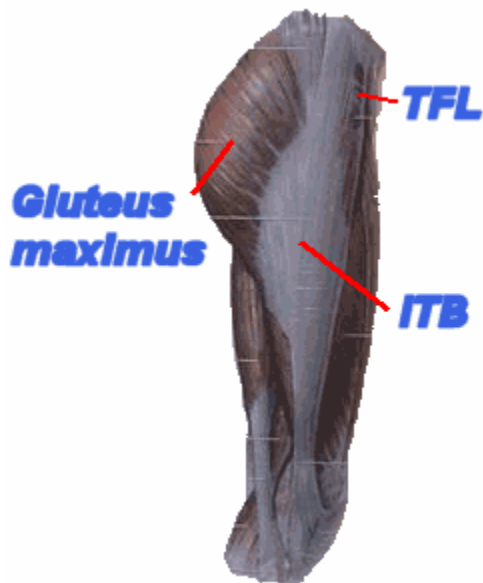
Innervation L4, L5, S1

Primary stabilizer of the hip and knee

Becomes underactive with a Left on right sacral torsion, right on left sacral torsion, and L4 or L5 mechanical problem often on the opposite side.

Under activity is a common cause of ITB syndrome or Patellar Femoral Pain Syndrome

Tensor Fascia Latae/Iliotibial band (TFL/ITB)



Innervation of TFL is L5-S1

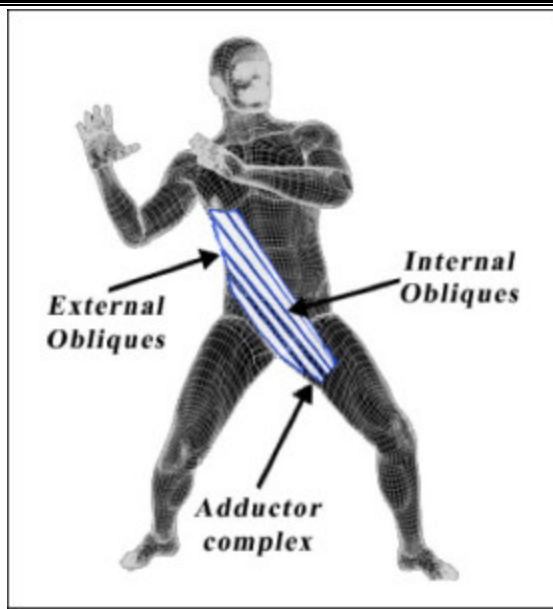
Under activity of the Gluteus Medius cause tightness in the ITB/TFL with chronic tightness.

Pelvic girdle muscle groups and slings

The 'pelvic girdle' simply refers to the enclosed structure that is formed from the collection of bones that make up the pelvis. Muscles that attach to the pelvis make up complimentary muscle groups called "slings". These muscle groups allow for either the production of movement or stabilization to reduce movement. However, these slings can sometimes be compromised due to structural misalignment in the SI joint.¹⁵

The **anterior oblique sling** that is composed of the serratus anterior, external and internal obliques, rectus abdominus, transversus abdominus, and lower limb adductors "provides stability by acting like an abdominal binder, compressing the entire pelvic girdle, especially the front, securing the symphysis pubis".⁶

When the adductors of the leg become overactive (hypertonic), they can distort the position of their attachment at the pelvis and cause an inferior shear at the pubic symphysis.



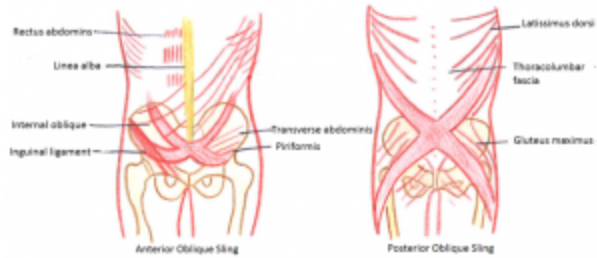
The **lateral sling** that is made of the gluteus medius, and adductors on one side of the body, as well as the quadratus lumborum (QL) on the other side provides lateral stability when walking.⁷ Usually, the gluteus medius can become underactive or hypotonic, resulting in abnormal positioning of the pelvis with ambulation.



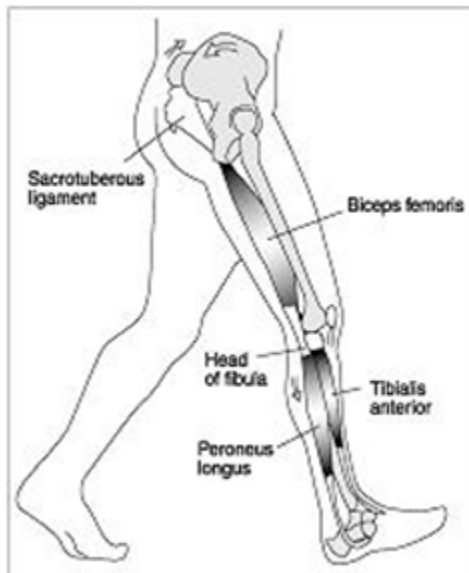
Figure 4. The lateral system
As she raises her leg in step class, the body must be stabilized atop the left leg. Contraction of the left gluteus medius and adductors stabilize the pelvis in concert with activation of the contralateral quadratus lumborum, which works to elevate the pelvis enough to ensure adequate freeway space for the swinging leg. Should the lateral system fatigue and the exerciser continue to follow the instructor, she will be forced to progressively rely on passive supports such as ligaments and discs in the pelvis and spine. Such lateral system dysfunction is a common source of injury in the back and legs.

The **posterior oblique sling** is composed of the latissimus dorsi, thoracolumbar fascia, and gluteus maximus (on the contralateral side from the latissimus dorsi).

“The action of these muscles along with the fascial system is thought to both fight the rotation of the pelvis that would occur during gait as well as store energy to create more efficient movement.”⁷ Muscle activity of the arms or legs influence each other via the Lumbar spine




The **deep longitudinal sling** is formed from the erector spinae muscle group, thoracolumbar fascia, and bicep femoris (portion of the hamstring). “The DLS uses both the thoracolumbar fascia and paraspinal system to create kinetic energy above the pelvis, while the biceps femoris acts as a relay between the pelvis and leg. This sling helps to create stability and help build as well as release kinetic energy to help more efficient movement.”⁷



Types of SIJD

Hypermobile or Loose SIJ



History of Trauma or hormonal change

Waddling gait


Secondary to lumbar pathology

Difficulty bending forward and standing on one leg (+forward flexion test and stork test on the same side)

Active straight leg will be easier with compression and SI belt/cores shorts may help with stability (link)

Response to mobilization, manipulation, taping, core stability when joint mechanics are improved, and prolotherapy (link)¹³

Excessive compression with ligamentous laxity



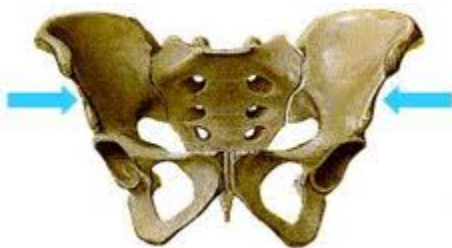Trauma over a short period of time or repetitive trauma over a long period of time

Difficulty bending forward and standing on one leg (+forward flexion test and stork test on the same side)

Active straight leg raise will not be easier with compression and SI belt and core shorts will not help.

Responds to Myofascial release, dry needling, mobilization, manipulation, taping, core stability when joint mechanics are improved, and prolotherapy (link)¹³

Hypomobile SIJ



Compressed joint due to muscle imbalance

Pain can switch sides

Pain is intermittent-can go away and return

Often an anterior rotation with left on right or right on left sacral torsion is observed

Over active piriformis causes toe out gait (link) and piriformis sciatica (link) on the same side.

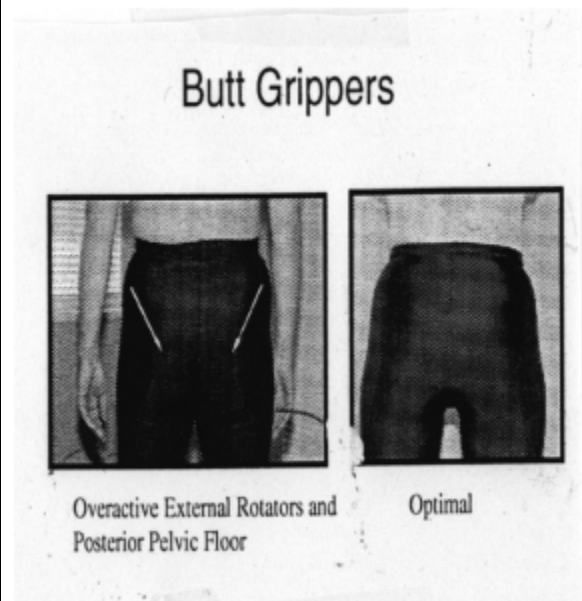
Able to stand on one leg

Able to lift both legs without compensation with the Active Straight leg test

Treatment is core stabilization and Myofascial release/dry needling¹³

Types of hypomobile SIJD

Absent Core



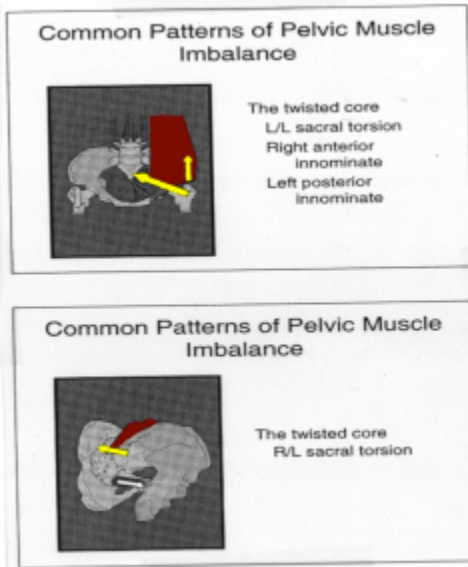
Can result from Post-partum

Butt-gripper (show pic)

Under active Transversus abdominus (core) and pubococcygeus (anterior pelvic floor- and may cause incontinence link to pic)

Over active piriformis both sides, multifidus and erector spinae (low back muscles, and posterior pelvic floor-may cause coccydria¹³

Twisted Core



The result of a unilateral (one sided) lumbar spine or SI joint dysfunction

Results in an Anteriorly rotated ilium and Left sacral torsion

Underactive unilateral Transversus abdominus (core), and/or multifidus and anterior pelvic floor

Over active unilateral piriformis and posterior pelvic floor

Inverted Core

Overactive multifidus and erector spinae muscles both sides¹³

Stiff Joint



The joint does not move secondary to Ankylosing spondylitis, capsular fibrosis, or joint fusion secondary to advanced age.

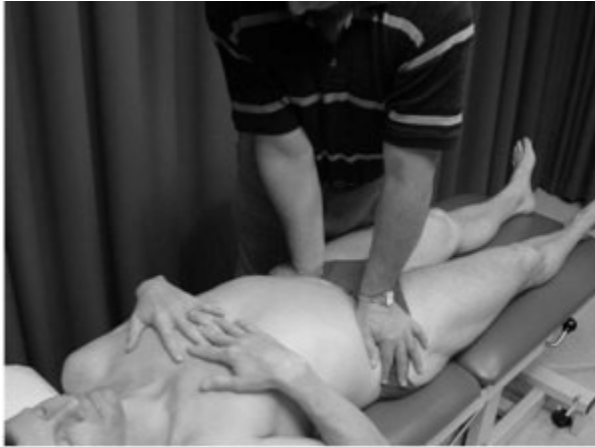Treatment is mobilization and flexion exercises

The SIJ joint has a hard end feel when mobilized ¹³

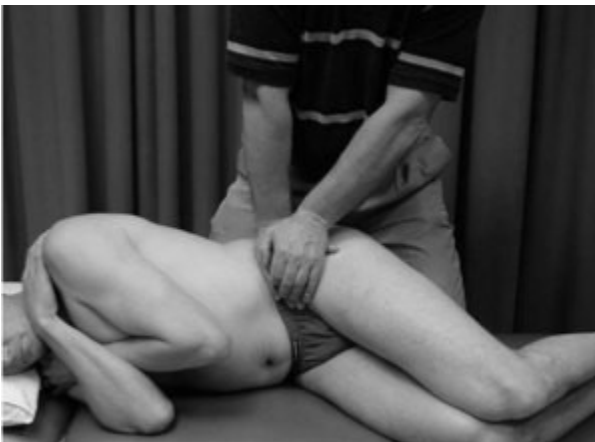Diagnostic Testing and Physical Exam

SI Joint Provocation Tests

SIJ testing should be done on patients with buttock pain, with or without lumbar or LE symptoms. Most SIJ is unilateral and around the PSIS. For all provocation tests, a + test is reproduction of symptoms and – test is no reproduction of symptoms.



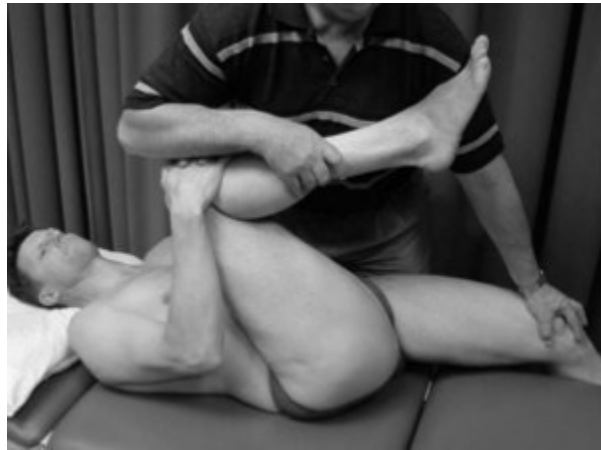Distraction Test: The patient is supine the examiner applies pressure to “spread” the ASISs.



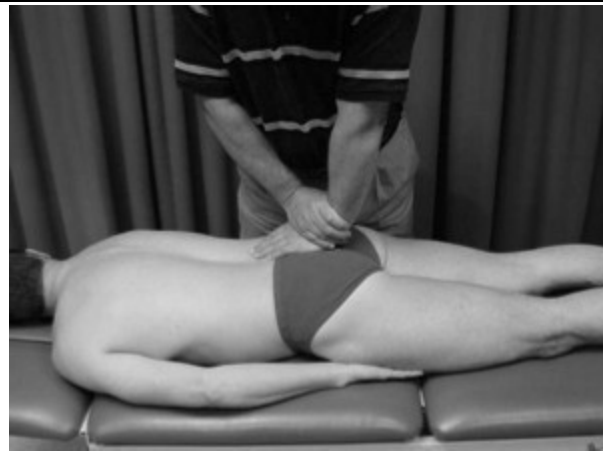Compression Test: The patient is in a side-lying position. The tester is behind the patient with both hands applying a downward pressure through the anterior portion of the ilium, spreading the SIJ.



Thigh Thrust Test: The patient is supine and the hip is flexed to 90 degrees and the knee is bent. The tester then applies a posterior shearing force to the SIJ through the femur. Avoid excessively adducting during this exam.



Gaenslen's Test (Right): The patient is supine lying near the side of table. The examiner stands on side of patients and places leg closest to them off edge of table. The examiner then instructs the patients to actively flex the opposite leg to their chest and hold. The examiner then applies pressure to the leg handing off edge of table forcing the hip into extension.



Sacral Thrust Test: The patient is prone and the examiner applies an anterior pressure through the sacrum.

2 out of 4 provocation tests (distraction, compression, thigh thrust or sacral thrust) have sensitivity of .88 and specificity of .78. + Likelihood ratio (LR) of 4.00 and – LR of .16 for SIJ pathology.


3 out of all 6 provocation have sensitivity of .94 and specificity of .78. + LR of 4.29 and – LR of .80 for SIJ pathology.

Laslett M, Aprill CN, McDonald B, Young SB. Diagnosis of Sacroiliac Joint Pain: Validity of Individual Tests and Composites of Tests. *Manual Therapy*. 2005; 10; 207-18.

SIJ Dysfunction Gold Standard Testing

The current 'gold standard' for diagnosing sacroiliac pathologies is a diagnostic nerve block, whereby anaesthetic is inserted into the SIJ, under fluoroscopy guidance. Some authors argue that if the patient achieves 50-75% pain relief, on 2 occasions with short and long acting nerve block, a diagnosis of SIJ dysfunction can be made, but with caution (van der Wurff et al 2006, Berthelot (cited Maigne et al)).

Fortin Finger test

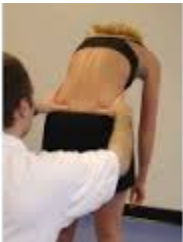

Simply place your finger directly on the area of your pain with ONE FINGER two times.

According to the results of this study, if you point to the exact spot where the sacroiliac joint is located (right or left) each time, your pain is likely coming from the SI joint. See diagram below for location of sacroiliac joints.

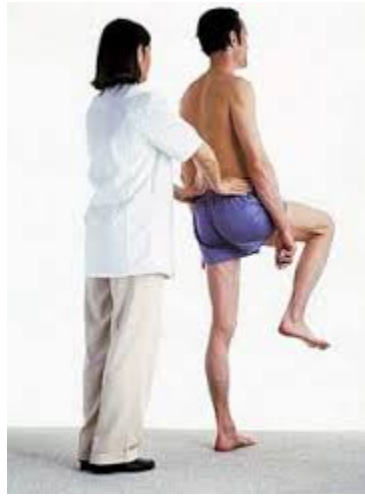The SI joints are located immediately below and to the inside of the posterior superior iliac spines (PSIS), which feel like small boney bumps on each side of your lower back. Either side can be painful

Standing Flexion test



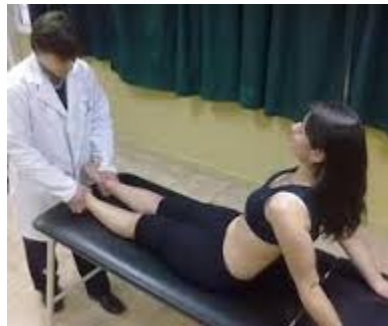The patient is instructed to bend forward from a standing position and the feet hip width apart, attempting to touch the floor while the therapist follows the PSIS's to see whether one appears to move more towards the head. If one of the PSIS's moves towards the head the test is considered positive. A positive test is suggestive of a SIJD on the positive side.

Stork test



The examiner places one thumb just below the PSIS and the other thumb on the sacral sulcus. With the patient in standing and arms unsupported, the patient is instructed to lift the tested side knee towards the ceiling until he has reached >90 degrees of hip flexion. If positive, there is a strong indication of SIJD present on that side. Normally, the PSIS should begin to drop down (inferiorly) after 90 degrees of hip flexion. This test is considered positive if the PSIS does not move or moves upward (superiorly) ³.

Long sit test

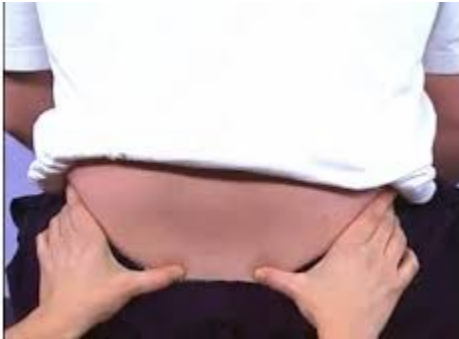

The examiner grasps the patient's legs above the ankles and fully flexes them, then extends them. The examiner then compares the two medial malleoli to see if a difference in position is present. Have the patient sit up, while keeping the legs extended. Compare the position of the medial malleoli again to see if there is a change. If there is a posterior innominate, the leg that appeared shorter will lengthen with the sit up (Or will go from short to long). If there is an anterior innominate, the leg that appeared longer will shorten with the sit up. (Or go from long to short). The affected side is label based on which side the examiner noticed a positive seated, standing, and /or stork test. This test can help in differentiating between a true leg length discrepancy and a functional leg length discrepancy due to a sacroiliac dysfunction.

Leg length measurement

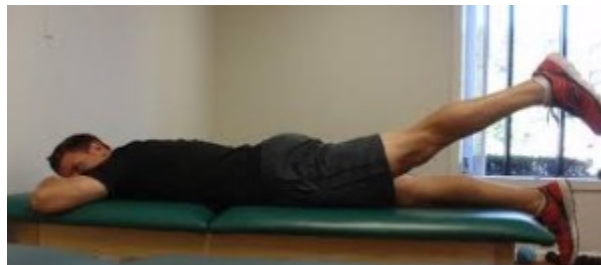A leg length measurement can be made with the patient in supine starting from underneath the ASIS and ending underneath the medial malleolus on the same side. Any difference noted will be a true leg length discrepancy and may be reason to introduce a heel lift or orthotic.

Seated flexion test



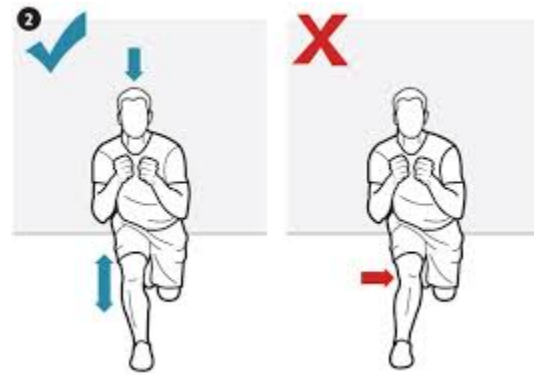
The patient is seated with the feet on the ground, arms between the knees, and the knees apart. The examiner places his thumbs underneath the PSIS's on both sides and asks the patient to bend forward as far as possible. If one thumb moves more towards the head then the test is positive. A positive test is suggestive of a SIJD on that side.³

Prone hip extension test



The patient lies on her stomach and lifts one leg with the knee straight about 6 inches off the table. The test is repeated on the opposite side. If one side seem significantly harder to do and /or there was a significant delay in the gluteus maximus contraction during hip extension then this side is positive. A positive test suggests gluteus maximus under activity and may be mean there is same side SIJD or a lumbar facet problem.

Single legged Squat test



The patient stands on one leg while the other leg is lifted off the ground in front of the body so that the hip is flexed to approximately 45° and the knee of the non-stance leg flexed to approximately 90°. The arms are held straight out in front, with the hands clasped together. From this position, squat down until about 60° knee flexion, and then return to the start position. Note the leg that was tested. If the knee buckles inward then the test is positive for poor hip stabilization and weak Gluteus medius.

Treatment and Exercises

Physical Therapy and other conservative treatments

A Physical Therapist uses a variety of manual therapy techniques, stretching, exercises, and modalities to address the source of a patient's pain; they also work to alleviate the aggravating symptoms that inhibit normal daily activities. The goal of Physical Therapy is not only to help a patient return to their pre-morbid status, but to help increase patients' body awareness so that they will become more independent in recognizing how they can treat their own pain through specific treatments tailored to individual needs.

Dry needling

An additional service offered by Physical Therapists for the treatment of SI joint and back pain, dry needling is quickly becoming a go-to treatment method. With the use of a very fine point needle, the therapist will locate the presence of a trigger point, which is a tightly bound group of muscle fibers that are hypersensitive and often cause pain, and insert the needle into that area. This process often causes instant relief of tension in the muscle group/joint.

Botox injections

Traditionally thought of as a tool for cosmetic procedures, Botox therapy can be used to reduce pain in chronically painful muscles. "These injections decrease the spasm of muscles that contribute to back pain, reduce the sympathetic response that is responsible for the deep-seated 'visceral' component of low back pain, and also help reduce the inflammatory response in and around the site of injection."

Steroid injections

In the human body, pain and inflammation go hand in hand. The inflammatory response of the body, although a natural process designed for protection of tissues and joints, can often be extremely debilitating. A cortisone injection is used to reduce inflammation (and thusly reduce pain). The medication takes effect rapidly, and is highly effective compared to an oral equivalent.

Prolotherapy

“Prolotherapy is an injection-based complementary and alternative medical therapy for chronic musculoskeletal pain; over several treatment sessions, a fairly small volume of an irritant or sclerosing solution is injected at sites on painful ligament and tendon insertions and in adjacent joint space during several treatment sessions.”¹¹ This treatment kick starts repair to the damaged tissue.

PRP

Platelet rich Plasma (PRP) involves drawing 20 cc's of blood, spinning the blood for 15 minutes in a centrifuge, extracting 3-4 cc's of PRP, and injecting the PRP directly into the site of injury using ultrasound guided imagery. A peppered needling technique is used during the injection to invoke an inflammatory response. The platelets have a lot of growth factor in them, which causes stem cells and other growth factors to come into the area. Eventually new collagen is formed and fills in the tear in the tendon. Research shows that PRP injections are not as beneficial as corticosteroid injections in the first 12 weeks following the injection, but PRP injections are much more beneficial after 12 weeks. At 2 years post injection the tendon actually looks normal and shows no signs of injury on an MRI, whereas the corticosteroids showed no long term benefits. Research is ongoing to investigate the affects of PRP for DDD and cartilage defects. There are currently no studies on PRP and SIJD. The cost of PRP varies from provider but is typically \$500-\$1000/shot.

Reference-Gosens T. Peerbooms JC. Van Laar W. Den Oudsten BL. Ongoing Positive Effects of PRP versus Corticosteroid Injection in Lateral Epicondylitis: A double blind randomized controlled trial with 2-year follow-up. AM J Sports Med 2011 39:1200

Adductor Ball Squeeze

reps: 5 sets: 1 hold: 5 Weekly: 5x Daily: 1x

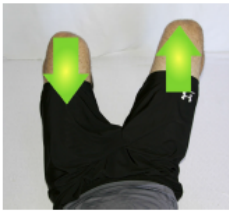


Step 1

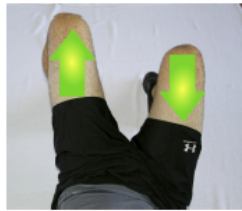
Lie on your back with knees bent and your feet flat on floor. Place a ball or pillow between your knees. Gradually squeeze your knees together until you reach a maximum contraction. Hold 2 seconds and gradually decrease the force of contraction until relaxed.

Hip shifts

reps: 10 sets: 3 Weekly: 5x Daily: 1x



Step 1

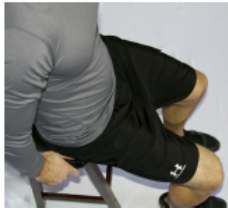

Step 2

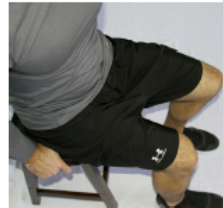Lie on your back with knees bent and feet flat on the floor. Keep feet still throughout. Move your right hip and knee backward as far as you can while moving your left hip and knee forward as far as you can. Repeat opposite direction.

Hip shifts- seated

reps: 10 sets: 3 Weekly: 5x Daily: 1x



Step 1



Step 2

Sit with knees bent and feet flat on the floor. Keep feet still throughout the exercise. Move your left hip and knee backward as far as you can while moving your right hip and knee forward as far as you can. Repeat opposite direction.

Pelvic clocks

reps: 10 sets: 3 Weekly: 5x Daily: 1x



Step 1

Lie on your back with knees bent and feet flat on the floor. Use your abdominals; do not push through feet. Roll your hips backward as you bring your navel towards the floor, bringing you to the 12 o'clock position. Roll your hips clockwise as you reach for every position on the clock until you return to the 12 o'clock.

Unilateral press ups (to correct R on L sacral torsion)

reps: 10 sets: 3 Weekly: 5x Daily: 1x



Step 1



Step 2

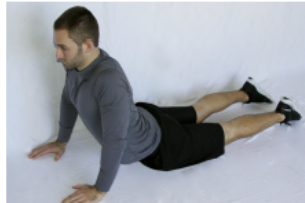Lie on your stomach with hands under your shoulders with the unaffected foot flat on the floor and the affected leg flat on bench. Keep your hips on the bench as you press through your hands to extend your back. Press up as high as your can without pain. Return to laying flat on your stomach. Perform on other side to correct left on right sacral torsion.

Press ups

reps: 10 sets: 3 Weekly: 5x Daily: 1x



Step 1



Step 2

Lie on your stomach with your hands under your shoulders. Keep your hips on the ground as you press through your hands to extend your back. Press up as high as you can without pain. Return to laying flat on stomach.

Lateral Shift Correction at Wall

reps: 10 sets: 3 Weekly: 5x Daily: 1x



Step 1



Step 2

Setup

- Begin in a standing upright position with one arm resting on a wall at your side and your other hand on your hip.

Movement

- Slowly let your hip to fall toward the wall, and hold this position.

Tip

- Make sure to maintain your balance during the exercise.

Standing Lumbar Extension

reps: 10 sets: 3 Weekly: 5x Daily: 1x



Setup

- Begin in a standing upright position with your hands resting on your hips.

Movement

- Slowly arch your trunk backwards and hold.

Tip

- Make sure to maintain your balance during the exercise and do not bend your knees.

Pelvic Clock



Directions: Lie on your back with your knees bent and your feet placed on the floor. Imagine that you have a clock on your stomach with the face pointing towards the ceiling. Roll your hips back towards 12 O'clock and flatten your back into the table. Now roll your hips forward to 6 O'clock and arch your lower back. Roll your left hip down towards 3 O'clock and then your right hip down towards 9 o'clock. To finish roll your hips around clockwise until you've reached every number on the clock.

Evaluation: Roll to each individual number on the clock and decide in which area(s) you are most restricted and/or have pain. When you find the number(s) in the clock that are restricted follow the treatment guidelines described on the handout for each number that you are having problems with. Alternatively, you can hold your pelvis 6 hours across or 180 degrees across from the number(s) in the clock that are restricted or painful for 1-2 minutes.

Reassessment: Repeat the directions above to see if you have cleared the restricted areas. You may need to repeat the exercises again to get the best results. You can perform the pelvic clock exercise as many times a day as necessary.

The pelvic clock can be performed in sitting.

Then pelvic clock can be performed in standing.

References

"Nutation/Counter Nutation – Yoga Anatomy." *Yoga Anatomy made simple- Information, articles, workshops, and DVDs*. N.p., n.d. Web. 12 Aug. 2013.

<<http://www.yoganatomy.com/2011/01/nutationcounter-nutation/>>.

"SI Joint Pain." *Medicine Net*. N.p., n.d. Web. 10 Aug. 2013. <www.medicinenet.com/sacroiliac_joint_p

3, 5 Issacs, Edward R. , and Mark R. Bookhout. *Bourdillion's Spinal Manipulation*. unknown: Butterworth-Heinemann, 2002. Print.

Greenman, Ph. E.. *Principles of manual medicine*. 2nd ed. Baltimore: Williams & Wilkins, 1996. Print.

6 "We've Heard So Much of the 'CORE', What About the 'SLINGS'? « Musculoskeletal Consumer Review. *Physiotherapy | Back, Neck, Shoulder and Knee Pain Specialists*. N.p., n.d. Web. 12 Aug. 2013.

<<http://www.coreconcepts.com.sg/mcr/weve-heard-so-much-of-the-core-what-about-the-slings/>>.

7 "Re-Thinking Functional Movement: The Sling Systems of the Body |

Breaking Muscle." *Breaking Muscle*. N.p., n.d. Web. 12 Aug. 2013.

<<http://breakingmuscle.com/strength-conditioning/re-thinking-functional-movement-sling-systems-body>>.

Jemmett, Rick. *Spinal stabilization: the new science of back pain*. 2nd ed. Halifax, N.S.: Novont Health Pub., 2003. Print.

"Internal Oblique Muscle | Actions | Attachments | Origin & Insertion." *GetBodySmart: Interactive Tutorials and Quizzes On Human Anatomy and Physiology*. N.p., n.d. Web. 12 Aug. 2013.

<<http://www.getbodysmart.com/ap/muscularsystem/abdominalmuscles/internaloblique/tutorial.html>

.

Reed, Stephen Charles, Penny Reed, and Michael H. Ford. *The complete doctor's healthy back bible: a practical manual for understanding, preventing and treating back pain*. Toronto: R. Rose, 2004. Print.

"Prolotherapy in primary care practice. [Prim Care. 2010] – PubMed – NCBI." *National Center for Biotechnology Information*. N.p., n.d. Web. 12 Aug. 2013.

<<http://www.ncbi.nlm.nih.gov/pubmed/20188998>>.

[Fortin JD](#), [Falco FJ](#), Am J Orthop (Belle Mead NJ). 1997 Jul;26(7):477-80. **The Fortin finger test: an indicator of sacroiliac pain.** Temple University Medical School, Philadelphia, Pennsylvania, USA.

[The Pelvic Girdle: An integration of clinical expertise and research, 4e](#) by Diane G. Lee BSR FCAMPT CGIMS (Nov 23, 2010)

Crossley KM, Zhang WJ, Schache AG, Bryant A, Cowan SM. *Performance on the single-leg squat task indicates hip abductor muscle function.* Am J Sports Med. 2011 Apr;39(4):866-73. Epub 2011 Feb 18

Johnson, Donald (Donald Hugh) *Practical orthopaedic sports medicine & arthroscopy* / Donald H.

Johnson, Robert A Pedowitz. p. ; cm. ISBN-13: 978-0-7817-5812-3